

INCIDENTAL BREAST PATHOLOGY DETECTED IN CHEST COMPUTER TOMOGRAPHY (CT)

Rana Alkrimeen, MD^{*1}, Asmaa Alqurqn, MD², Ayat Alalwan, MD³, Hend Harahsheh, MD⁴ & Diana Aljammal, MD⁵

^{*1}Amman, Jordanian Royal Medical Service, Radiology Department

²Amman, Jordanian Royal Medical Service, Pediatric Department

³Amman, Jordanian Royal Medical Service, Radiology Department

⁴Amman, Jordanian Royal Medical Service, Radiology Department

⁵Amman, Jordanian Royal Medical Service, Radiology Department

Abstract

Objective

Keywords:

Chest Computer tomography (CT), breast lesions.

To emphasize the importance of requested chest CT scan for cardiothoracic conditions for radiologist to evaluate the breast area this may impact patient's management.

Material and method

A total number of 130 female patients whom underwent chest CT for cardiothoracic reasons, were retrospectively reviewed their images to evaluate and characterize breast lesions in a period between June 2016 –December 2017 at King Hussein Medical Center. The age of the patient's ranges from (20-70 years) with the mean age 45 years. All scans were performed with Siemens definition dual source 64 slice CT scan, chest CT scan protocol with intravenous (IV) contrast media.

The results will be analyzed by simple statistical method.

Introduction

The basic and the preferred imaging modalities to assess breast pathology are mammography, ultrasound and magnetic resonance imaging MRI [1]. However, computer tomography (CT) can detect breast lesions incidentally during scanning for other pathology reasons in the lung, heart, mediastinum and chest wall [2] especially during the last years, where the spatial and temporal resolution have been significantly improved. Consequently, there is an increase in the detection and even more characterization of the breast lesions which is incidentally found in the mentioned reasons [3].

The aim of the study is to highlight the importance of evaluating and reviewing the breast in chest CT scan as a routine in the interpretation of the images for radiologist which may lead to recognize any pathology that affect patient's management.

Materials and methods

This is a retrospective study that was collected from patients who underwent multi-slice chest CT scan for various conditions at king Hussein Medical Center. All patients were scanned with Siemens definition dual source 64 slice CT scan in a period from January 2016 to December 2017. The word "breast" was obtained from the reports in our local data system, we found 1259 patients, excluding the patients known to have breast pathology, male patients and lactating females. We reviewed the images, and then correlated the findings with mammography and ultrasound. The study involved Chest CT scan with contrast media and the parameters were: the slice thickness 5mm and 3mm, the 120 KVP and (60-100) MAs. In all studies the breast tissue was totally included in the scan. Our study had ethical committee approval from our institution and all data was obtained lawfully

Result

Our study included a total number of 1259 patients that have the word breast in the reports, after excluding patient known previous pathology, male and lactating patients we ended with 130 female patients with the age range from (20-70 years) and the main age was 45 years. Then we reviewed the images and classified the pathology according to the CT scan features of the lesions and the associated findings into three groups based on the features of the lesions : mostly malignant lesions [figure 3]: 14 patients (10.8%), mostly benign lesions [figure 1]: 50 patients (38.4%) and undetermined lesions [figure 2]: 66 patients (50.7%). For further characterization; the other basic modalities for breast assessment including the mammography and the ultrasound in addition to histopathology results were obtained for definite diagnosis. Regarding the first group 9 out of 14 was proven to be primary malignant breast tumors, fortunate; no malignancy was found in the second group, interestingly in the third group 2 out of 66 patients were proven to have malignant lesions while 50 patients were normal as dense glandular tissue and 14 patients had benign pathology. All the results were added together as the following: primary breast malignancy [Table 1] 11 patients (8.2%) and the majority were invasive ductal carcinoma in 7 patients, while benign breast lesions [Table 2] 67 patients (51.5%) were the fibroadenoma the most common finding in 30 patients and normal breast were 52 patients (40%).

Discussion

Incidental breast pathology can be detected while scanning the thoracic area for another reason by CT scan, although it is not the primary modality to assess breast pathology. Many studies have the same experience; such as Swensen et al reported cancer in three patients out of 750 (0.4%) women during screening for lung cancer [4]. Shojaku et al reported cancer in four patients out of 1008 (0.4%) either primary or metastatic breast tumor in non contrast study [5]. Monzawa et al reported cancer in ten patients out of 2945 (0.34%) [6]. Poyraz et al found 12 patients out of 1872 (0.53%) that had breast tumor [1]. In our study we found 11 out of 1259 patients (0.8%) who had breast cancer proven histopathologically, that is almost consistent with other studies. Although the CT scan is not the modality of choice to assess breast, there are features and findings that helps in suggesting the diagnosis. For example, the suspicious malignant features include: A spiculated mass with irregular shape and margin, in addition, the associated findings include skin thickening, axillary lymphadenopathy and invasion of the adjacent structures [4], while the benign lesions feature includes: well-defined lesions with regular or smooth margin and most of time not associated with other findings [7]. However, the benign looking features not excluding the malignancy which indicates further assessment by mammography and ultrasound and even biopsy in some cases. In young patients the glandular tissue makes the evaluation suboptimal as might obscure the lesion, or may lead to overestimation of the lesions that appears as irregular areas and need confirmation by ultrasound in most of the cases.

The limitation we are not included the breast calcifications in our study.

Conclusion

Evaluation of the breast in chest CT scan for thoracic area pathology reasons can detect hidden or subclinical breast lesions, which help in early diagnosis and early management of patients.

References

1. Necdet Poyraz, Ganime Dilek Emlik, Suat Keskin, Havva Kalkan. *Incidental Breast Lesions Detected on Computed Thorax Tomography. J Breast Health* 2015; 11: 163-7.
2. L. Batista¹, J. Ressurreição¹, I. Marques², J. T. Soares³, A. Almeida¹, P. Coelho⁴; ¹Vila Nova de Gaia/PT, ²Vila Nova de Gaia, Porto/PT, ³Madalena- Vila Nova de Gaia/PT, ⁴44434-502 Vila Nova de Gaia/PT. *Incidentally breast findings on a thoracic CT study - what should we look for?*. 10.1594/ecr2013/C-1647.
3. Monica G. Harish, MD², Sheela D. Konda, MD, PhD², Heber MacMahon, MB, BCh, Gillian M. Newstead, MD. *Breast Lesions Incidentally Detected with CT: What the General Radiologist Needs to Know. RadioGraphics* 2007; 27:S37-S51. Published online 0.1148/rg.27si075510.
4. Swensen SJ, Jett JR, Hartman TE, Midthun DE, Sloan JA, Sykes AM, Aughenbaugh GL, Clemens MA. *Lung Cancer Screening with CT : Mayo Clinic Experience I. Radiology* 2003; 226:756-761. (PMID: 12601181)
5. Shojaku H, Seto H, Iwai H, Kitazawa S, Fukushima W, Saito K. *Detection of incidental breast tumors by noncontrast spiral computed tomography of the chest. Radiat Med* 2008; 26:362-367. (PMID: 18677611)

6. *Monzawa S, Washio T, Yasuoka R, Mitsuo M, Kadotani Y, Hanioka K. Incidental detection of clinically unexpected breast lesions by computed tomography. Acta Radiologica 2013; 54: 374-379. (PMID: 23395815).*
7. *P MOYLE, MBChB, MRCP, FRCR, L SONODA, MBBChir, PhD, FRCR, P BRITTON, MBBS, FRCR and R SINNATAMBY, MBBChir, MRCP, FRCR. Incidental breast lesions detected on CT: what is their significance?. The British Journal of Radiology, 83 (2010), 233–240*

Table 1

Malignant lesions	
Diagnosis	Number (n=11)
Invasive ductal carcinoma	7
Invasive lobular carcinoma	1
Mucinous carcinoma	3

Table 2

Benign lesions	
Diagnosis	Number (n=67)
fibroadenoma	30
Cysts	25
Dilated ducts	5
Intra-mammary lymphnodes	3
Abscess	3
Phyllodes tumor	1

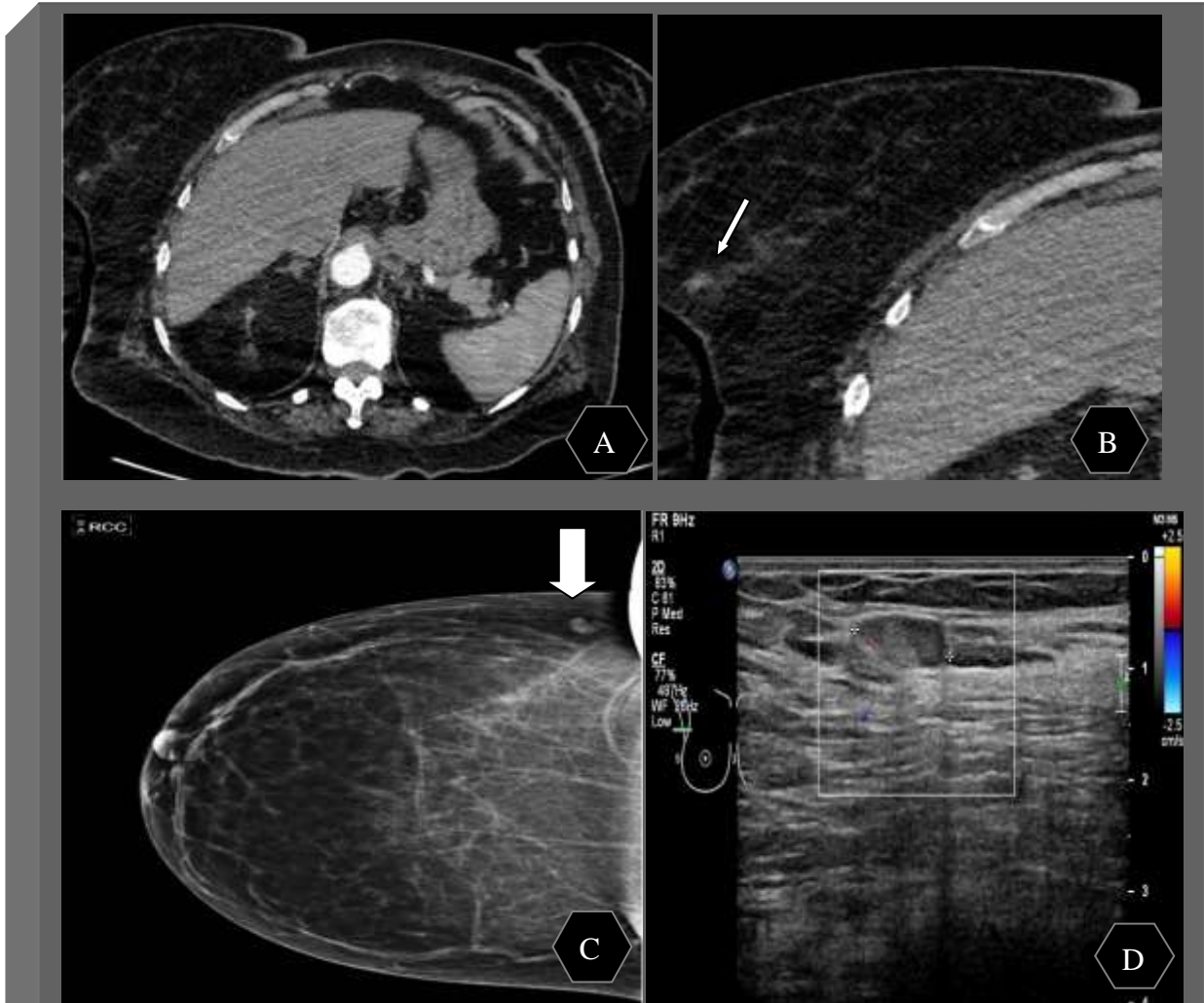
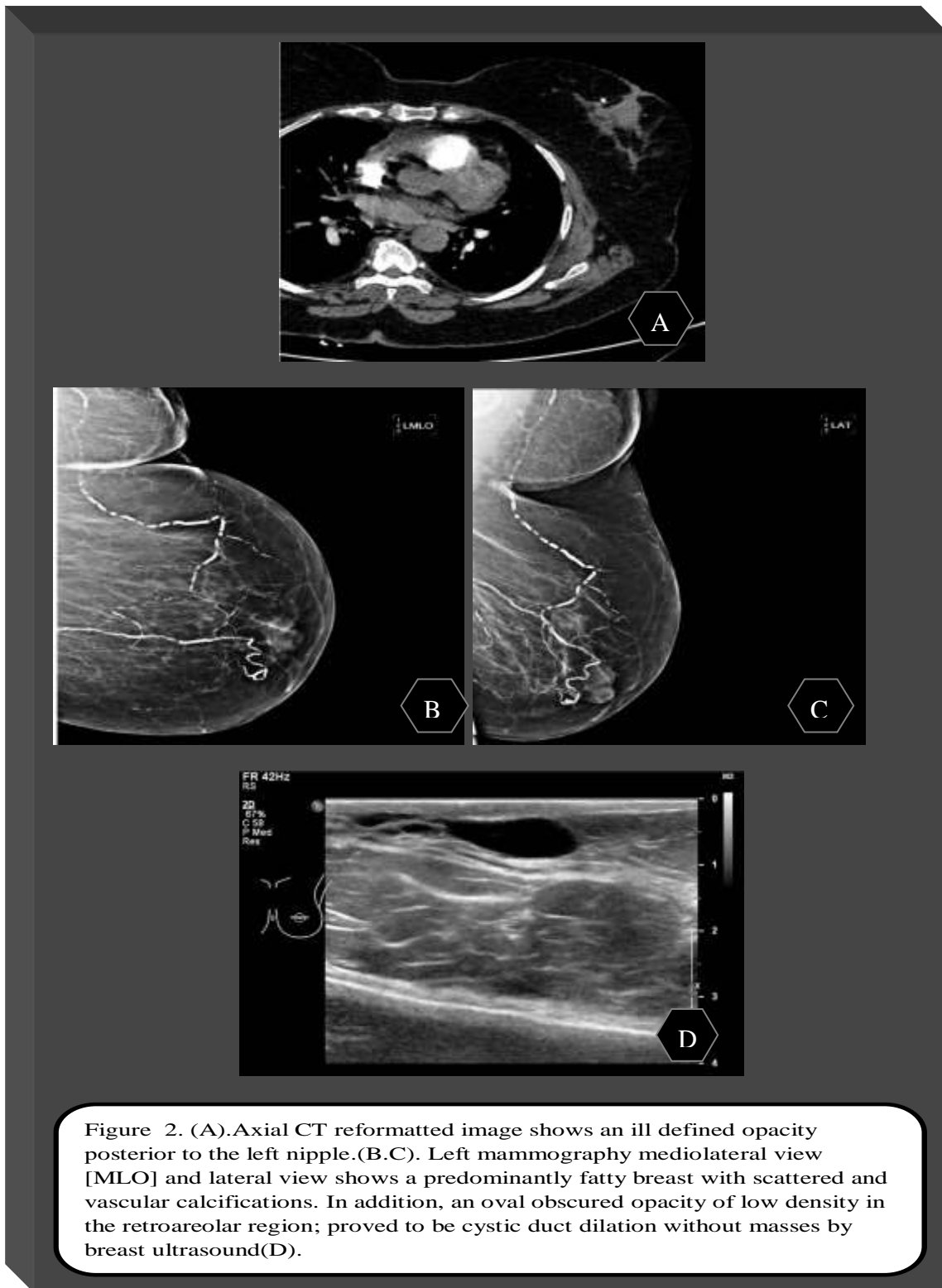


Figure1. (A,B). Axial CT reformatted images shows small ill defined soft tissue lesion in right breast, more obvious in magnified image[white arrow].(C). Right breast mammography craniocaudal view [CC] shows a small oval opacity in the upper outer quadrant [UOQ] measures 10 mm [wide white arrow] confirmed by breast ultrasound an intramammary lymph node (D).



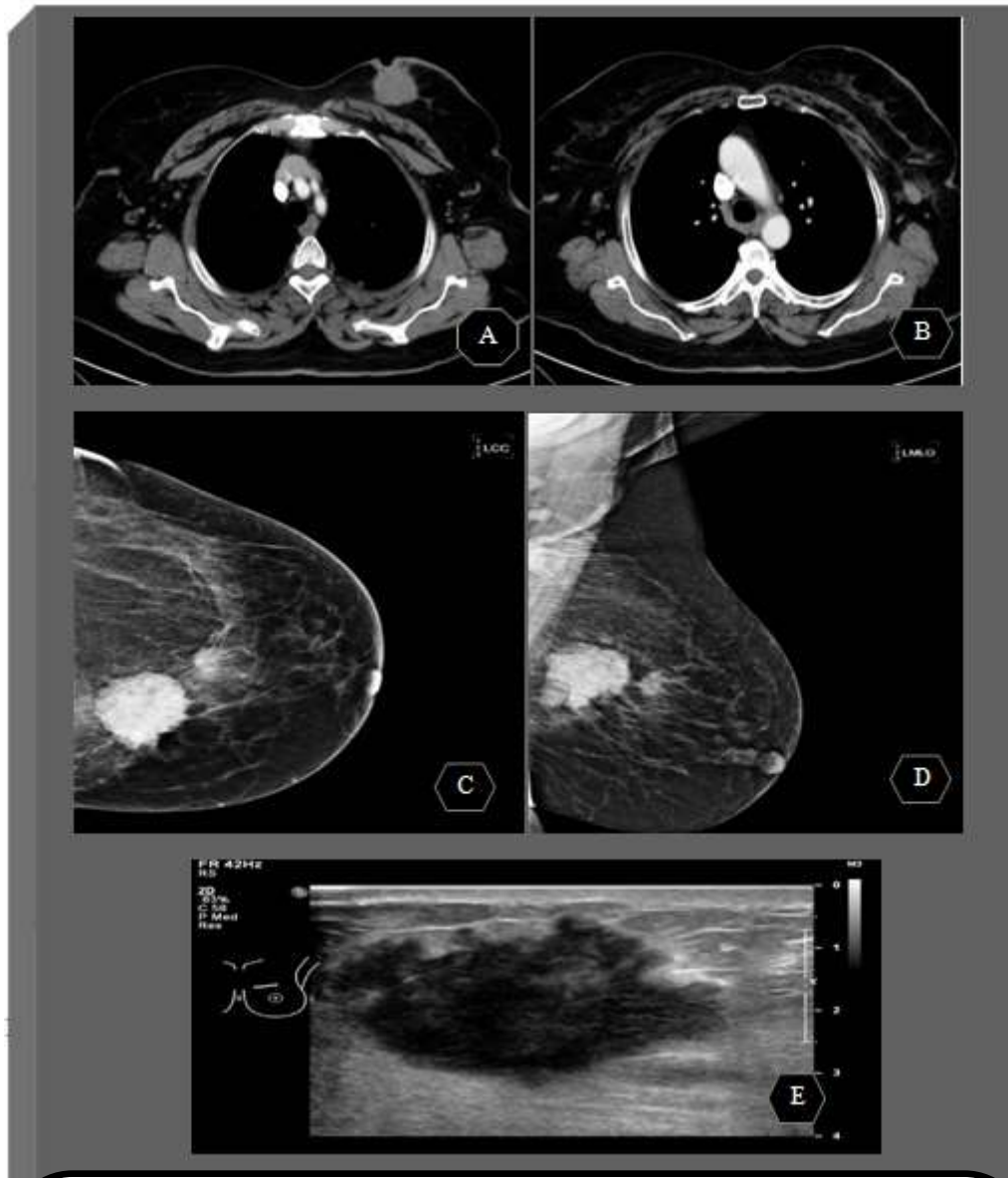


Figure 3.(A,B)axial reformatted images show soft tissue mass in left breast fungating to the skin associated with skin thickening and left axillary lymphnodes.(C,D) left mammography craniocaudal view[CC] and mediolateral view[MLO] shows an irregular mass in the mid inner aspect posteriorly measures 5.3 X4.8 cm with adjacent irregular mass measures 1.8 cm ,associated diffuse mild skin thickening .(E) breast Ultrasound shows an irregular hypoechoic mass in Lt breast upper inner quadrant[UIQ] highly suspicious.